

# A novel preoperative ultrasonography protocol for prediction of bichectomy procedure

Filipe Jaeger<sup>1,2,3</sup>

Carlos Henrique Bettoni Cruz de Castro<sup>2</sup>

Gabriella Marques Pinheiro<sup>1</sup>

Ana Cristina Rodrigues Antunes de Souza<sup>3</sup>

Gui Tarcisio Mazzoni Junior<sup>4</sup>

Ricardo Alves de Mesquita<sup>1</sup>

Gustavo Batista Menezes<sup>5</sup>

Leandro Napier de Souza<sup>1</sup>

1 – Universidade Federal de Minas Gerais

2 – Pontifícia Universidade Católica de Minas Gerais

3 – Centro Universitário Newton Paiva

4 – Maternidade Odete Valadares, Fundação Hospitalar do Estado de Minas Gerais

5 – Centro de Biologia Gastrointestinal, Universidade Federal de Minas Gerais

[filipe@maxillofacialtips.com](mailto:filipe@maxillofacialtips.com) / [leandronapierdesouza@gmail.com](mailto:leandronapierdesouza@gmail.com)

## ABSTRACT

The aim of the present study was to evaluate the use of preoperative ultrasonography as a complementary diagnostic tool to aid in the decision of bichectomy procedure. Thirty-two patients, more than 18 years, with aesthetics and functional complaints were clinical evaluated by three experienced surgeons and previous selected to bichectomy procedure. The study sample consisted of 29 females (ranged from 21 to 46; mean 26.7 years) and 3 males (ranged from 31 to 40; mean 36.0 years). After the ultrasonography, the surgical procedure was contraindicated in nine patients (28.12%) based in buccal fat pad volume. The ultrasonography proved to be an effective tool to improve the diagnosis and clinical decision avoiding unnecessary surgeries and diminishing unreal expectations from the patients.

**Key words:** Buccal fat pad. Bichectomy. Ultrasonography

## INTRODUCTION

The buccal fat pad (BFP) was first described by Marie François Xavier Bichat, a French anatomist, physician and biologist (1771-1802), as a trigone-shaped adipose tissue located in the cheek<sup>1</sup>. Within the last decades the BFP was extensively studied, including functional and aesthetics clinical uses. Numerous functions have been presumed to BFP, including suckling, contributing to mastication, protection and cushioning of neurovascular bundles, separating the muscles of mastication from one another, amongst others<sup>2</sup>.

According the location of the buccal fat pad, it is prone to undergo clinically significant pathologies such as lipoma<sup>3</sup>, herniation, and

pseudoherniation<sup>4</sup>. The location, however, also allows permit the surgeons cover several oral defects and lesions including congenital palatal defects, numerous neoplastic lesions and osteonecrosis related to bisphosphonates<sup>5,6</sup>. Nowadays, bichectomy or facial lipectomy is a surgical procedure in great evidence worldwide due to the improvement of facial aesthetics appearance<sup>7</sup>. Nevertheless, the function is the main indication in the Oral and Maxillofacial Surgery field for those patients with cheek chewing habit (morsicatio buccarum).

The clinical evaluation has been used as the only method to indicate the surgical procedure<sup>4,7,8</sup>. In some cases, the surgeons may overrate the amount of BFP

and face to low volume or absence of it. There is a lack in the literature according features that can help the surgeons before the bichectomy procedure. Thus, new tools should be used to improve the diagnosis avoiding unnecessary surgeries and establishing limits to the patients' expectation regarding the outcome. So, the aim of this study is to propose the use of preoperative ultrasonography (USG) as a complementary diagnostic tool to aid in the decision of bichectomy procedure.

### PATIENTS AND METHODS

This study was approved by the human research ethics committee and a informed written consent was obtained from all participants. Thirty-two patients, more than 18 years, with aesthetics and functional complaints were clinical evaluated by three experienced surgeons and previous selected to bichectomy procedure. The study sample consisted of 29 females (ranged from 21 to 46; mean 26.7 years) and 3 males (ranged from 31 to 40; mean 36.0 years). All the cases were evaluated preoperatively by a single physician for volumetric analysis of the BFP. The ultrasound machine used was Medison Accuvix XG – Samsung with multifrequencial linear transducer (7 – 10 MHz).

### RESULTS

First of all, the goal was to identify the BFP a hipoecic structure anteriorly to anterior boundary of masseter muscle, deeply to the subcutaneous tissue and superficially to the buccinator muscle (Fig 1). Considering that BFP is a fat tissue, it has ecogenic linear images that represent conjunctive tissue permeating it and it is very compressible. This last characteristic is an auxiliary tool to identify the BFP. In order to make a correct volume evaluation, it's necessary an extremely gentle compression of the face, due to the BFP form (similar to a triangle) that suffers great change with a lighter effort over face skin.

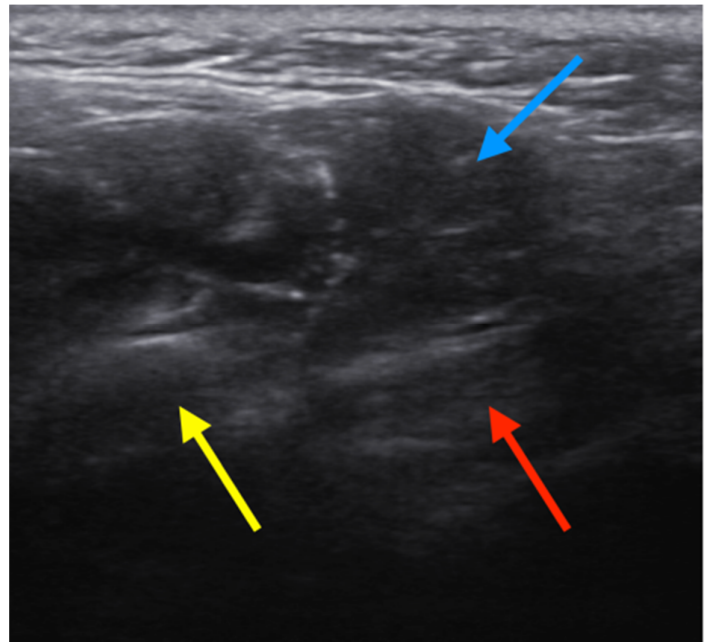


Figure 1: BFP relationship with anatomical structures. Blue row, BFP; Red row, buccinator muscle; Yellow row, masseter muscle

The second step was freeze two images, one that display the larger diameter and another in the perpendicular plane of the first. In this way, it was possible to estimate the volume after the measure of the three orthogonal planes (Fig 2).

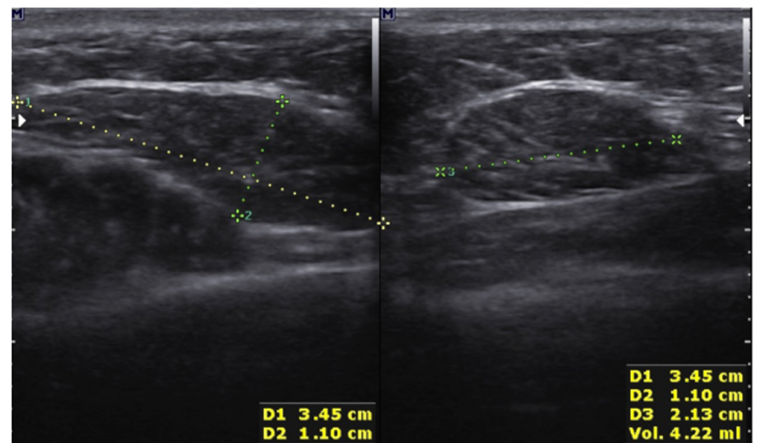


Figure 2: BFP volume estimation based on three orthogonal planes. D1, D2, D3 represent three orthogonal planes used to estimate the BFP volume. Vol, represents the estimated volume

The clinical profiles and data of 32 patients who underwent to bilateral ultrasound exam for BFP evaluation are presented in Table 1. The Fig 3 shows examples of small, medium and big BFP. The study sample consisted of 90.62% of females and 9.38% of males.

After the USG, the surgical procedure was contraindicated in nine patients (28.12%) based in BFP volume. In those cases, the BFP was too small or absent. Also, it was interesting to observe that USG is able to reveal putative differences between the right and left BFP (Fig. 4).

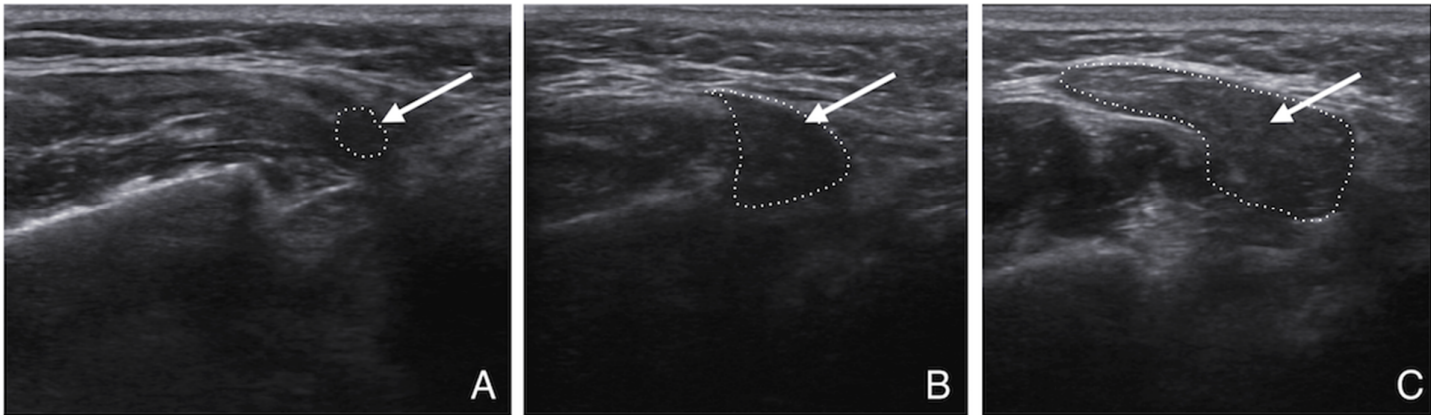


Figure 3: Examples of BFP size variability. A, small; B, medium; C, Big

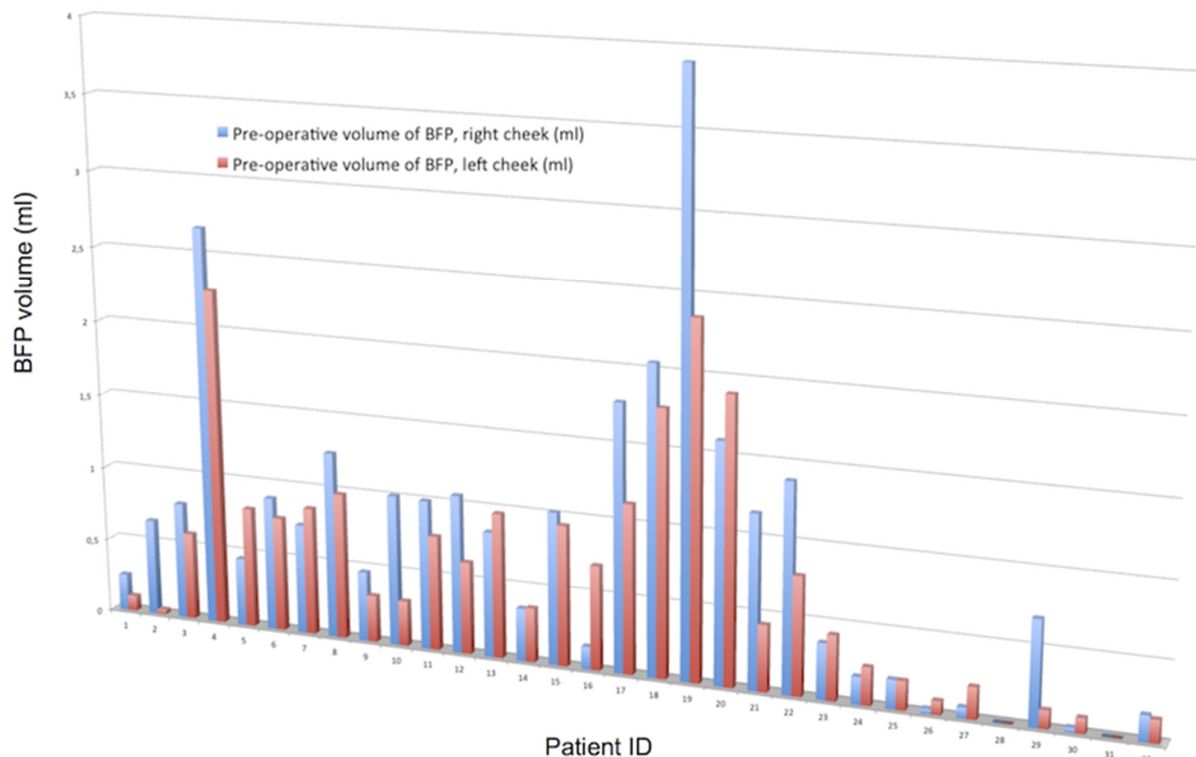


Figure 4: Demonstration of the different volumes of right and left BFP between the same patients

Table 1. Clinical data of the patients who underwent to bilateral ultrasound exam.

Patient	Gender	Age (years)	Pre-operative volume of BFP, right cheek (ml)	Pre-operative volume of BFP, left cheek (ml)
1	F	26	0,25	0,10
2	F	22	0,65	0,03
3	F	29	0,79	0,59
4	F	23	2,67	2,26
5	F	46	0,46	0,81
6	M	37	0,90	0,77
7	F	24	0,74	0,86
8	F	22	1,25	0,98
9	F	40	0,47	0,31
10	F	27	1,01	0,30
11	F	23	1,00	0,77
12	F	22	1,06	0,62
13	F	21	0,84	0,97
14	F	21	0,35	0,36
15	F	31	1,02	0,94
16	F	26	0,15	0,70
17	M	31	1,78	1,13
18	F	28	2,05	1,77
19	M	40	3,91	2,36
20	F	28	1,60	1,90
21	F	29	1,16	0,44
22	F	23	1,39	0,79
23	F	30	0,37	0,43
24	F*	29	0,18	0,25
25	F*	21	0,19	0,19
26	F*	23	0,03	0,09
27	F*	23	0,07	0,21
28	F*	32	0,00	0,00
29	F*	25	0,69	0,12
30	F*	25	0,03	0,10
31	F*	26	0,00	0,00
32	F*	28	0,17	0,15
Mean(SD)			Mean(SD)	
(n=32) 0.85			(n=33) 0.66	
(0.84)			(0.62)	

F female, M male, \* patients in whom BFP volume was too small or absent

## DISCUSSION

The present study aimed to verify the use of preoperative ultrasonography as a complementary diagnostic tool for bichectomy procedure. If we consider that nine patients (28.12%) could be submitted to the surgery without real indications, the USG emerges as potential tool in the pre-surgical analysis of bichectomy candidates. In cases of BFP asymmetry, a doubt is raised about the indication of surgery to avoid the development of facial asymmetry after the procedure. Furthermore, when a small BFP is present the surgeon could discuss the case with the patient regarding results, diminishing unreal expectations.

The USG is an established method of diagnosis to study soft tissues of the body. Based on sound waves, without radiation, noninvasive, inoffensive and accessible in worldwide due to its inexpensiveness<sup>9</sup>. On literature search there are no available studies that have evaluated the USG as complementary tool diagnostic tool prior to bichectomy procedure. An adequate technique is necessary from the operator. So, since the BFP is extremely soft with a relevant compressibility, the operator needs to manipulate the transducer with tenderness, exerting minimal compression on the patient's face to avoid change of the shape and volume of the BFP.

A recent paper evaluated the BFP volume as an interposition material for the management of temporomandibular joint ankylosis<sup>10</sup>. Although the authors asked the patients to fill the cheek with air we didn't recommend because this maneuver distend the BFP and make an inadequate result in the the USG evaluation of its volume. Other important aspect is how to estimate the BFP volume. Using 2D images, the volume can be inferred from at least two orthogonal planes but never based on unique plane.

Other tools such computed tomography (CT) and magnet resonance imaging (MRI) have been used to determine the BFP volume in anatomic studies [11]. Considering the disadvantages of CT (ionizing radiation and contrast agents) and MRI

(reduced availability, long examination times and high cost), the authors reinforce that the USG is the best choice for BFP volume evaluation.

In conclusion, this study represents an innovation by the introduction of a new application of a known technique. The USG proved to be an effective tool to improve the diagnosis and clinical decision avoiding unnecessary surgeries and diminishing unreal expectations from the patients.

## REFERENCES

- 1- Bichat F. Anatomie Generale, Applique a la Physiologie. Medecine. **Brosson Gabon and Cie**, Paris; 1801.
- 2- Yousuf S, Tubbs RS, Wartmann CT, Kapos T, Cohen-Gadol AA, Loukas M. A review of the gross anatomy, functions, pathology, and clinical uses of the buccal fat pad. **Surg Radiol Anat**. 2010;32:427-436.
- 3- Furlong MA, Fanburg-Smith JC, Childers EL. Lipoma of the oral and maxillofacial region: site and subclassification of 125 cases. **Oral Surg, Oral Med, Oral Pathol, Oral Radiol and Endod**. 2004; 98(4):441-450.
- 4- Matarasso A. Pseudoherniation of the buccal fat pad: a new clinical syndrome. **Plast Reconstr Surg**. 1997;100:723-730.
- 5- Castro CH, Souza LN, Melo FS. Use of the buccal fat pad as a free graft for closure of orinasal fistula in a cleft palate patient. **The Journal of Craniofacial Surgery**. 2015;26(1):14-16.

- 6- Rotaru H, Kim M-K, Kim S-G, Park Y-W. Pedicled buccal fat pad as a reliable surgical strategy of the treatment of medication-related osteonecrosis of the jaw. **Journal of Oral and Maxillofacial Surgery**. 2015;73:437-442.
- 7- Stevao EL. Bichectomy or Bichatectomy – A small and simple intraoral surgical procedure with great facial results. **Advancer in Dentistry and Oral Health**. 2015;1(1):1-4.
- 8- Jackson IT. Buccal fat pad removal. **Aesthetic Surg J** 2003;23:484-485.
- 9- Li C, Su N, Yang X, Yang X, Shi Z, Li L. Ultrasonography for detection of disc displacement of temporomandibular joint: a systematic review and meta-analysis. **J Oral Maxillofac Surg**. 2012;70:1300-1309.
- 10- Bansal V, Bansal A, Mowar A, Gupta S. Ultrasonography for the volumetric analysis of the buccal fat pad as an interposition material for the management of ankylosis of the temporomandibular joint in adolescent's patients. **Brit J Oral Maxill Surg**. 2015;53:820-825.
- 11- Xiao H, Bayramiçli M, Jackson IT. Volumetric analysis of the buccal fat pad. **Eur J Plast Surg**. 1999;22:177-181.